

Ivan BRISTOW^{1,a}
 Wen Chean LIM^{2,a}
 Alvin LEE^{2,3}
 Daniel HOLBROOK²
 Natalia SAVELYEVA⁴
 Peter THOMSON⁵
 Christopher WEBB⁶
 Marta POLAK²
 Michael R. ARDERN-JONES^{2,3}

¹ Faculty of Health Sciences,
 University of Southampton, UK

² Clinical Experimental Sciences,
 Faculty of Medicine,
 University of Southampton, UK

³ Department of Dermatology, University
 Hospitals Southampton NHS Foundation
 Trust, Southampton, UK

⁴ Cancer Sciences, Faculty of Medicine,
 University of Southampton, UK

⁵ The Podiatry Centre, Dunfermline, UK

⁶ The Podiatry Centre, Portsmouth, UK

^a These authors contributed equally

Reprints: M. R. Ardern-Jones
 <m.aj@soton.ac.uk>

Microwave therapy for cutaneous human papilloma virus infection

Background: Human papilloma virus (HPV) infects keratinocytes of the skin and mucous membranes, and is associated with the induction of cutaneous warts and malignancy. Warts can induce significant morbidity and disability but most therapies, including cryotherapy, laser, and radiofrequency devices show low efficacy and induce discomfort through tissue destruction. Microwaves are readily capable of passing through highly keratinised skin to deliver energy and induce heating of the tissue in a highly controllable, uniform manner. **Objectives:** To determine the effects of microwave on cutaneous HPV infection. **Materials & methods:** We undertook a pilot study of microwave therapy to the skin in 32 consecutive individuals with 52 recalcitrant long-lived viral cutaneous warts. Additionally, we undertook a molecular characterisation of the effects of microwaves on the skin. **Results:** Tissue inflammation was minimal, but 75.9% of lesions cleared which compares favourably with previous studies showing a clearance rate of 23-33% for cryotherapy or salicylic acid. We show that microwaves specifically induce dendritic cell cross-presentation of HPV antigen to CD8+ T cells and suggest that IL-6 may be important for DC IRF1 and IRF4 modulation to enhance this process. **Conclusion:** Keratinocyte-skin dendritic cell cross-talk is integral to host defence against HPV infections, and this pilot study supports the concept of microwave induction of anti-HPV immunity which offers a promising approach for treatment of HPV-induced viral warts and potentially HPV-related cancers.

Key words: warts, microwave, CD8+ T cells, HPV

Article accepted on 17/03/2017

Cutaneous HPV infection is common and warts are thought to affect most people at some time during their lives. Point prevalence estimates range from 0.8% to 4.7% of the population and two million people seek medical advice about warts each year in the UK [1], yet treatment options are poor and a meta-analysis has shown no significant benefit over placebo [2]. Although skin is most frequently infected by “non-oncogenic” HPV, most HPV-associated skin squamous cell carcinomas are diagnosed in persistent and recalcitrant verrucae and the majority contain HPV16 [3].

HPV infects the basal epithelial cells of cutaneous and mucosal keratinised epithelia and infection is mainly controlled by T cell-mediated immunity [4]. HPV-specific CD8+ lymphocytes are critical for clearance of HPV viral warts [4] and individuals treated with immunosuppression to prevent organ graft rejection do not clear HPV infections. In healthy individuals, induction of HPV-specific CD8+ T cells with topical imiquimod (TLR7 agonist) has been shown to facilitate wart clearance [5, 6]. However, tissue penetration is a limiting factor for the therapeutic potential of imiquimod on most non-mucosal sites.

Other modalities of thermal ablation have previously been investigated for the treatment of warts [7-10]. Direct heat ablation is now rarely used because of scarring and subse-

quent morbidity. The most widely used physical modality is liquid nitrogen application (cryotherapy) to the skin [11]. This causes tissue destruction and in a recent meta-analysis of randomised controlled trials, this therapy has been shown to have low efficacy in the management of common warts (with a mean clearance on all sites of 49%) [12]. Microwaves (30 MHz to 30 GHz) exist in the electromagnetic spectrum between radiofrequency and visible light and have been widely used as a means for delivering heat energy to induce thermal ablation in the treatment of cancer, especially for inoperable liver tumours [13], but have not been previously applied to skin. Recent technological advances have enabled development of a hand-held device to deliver targeted application of microwave therapy to skin. We set out to test the potential of this new modality as a treatment for warts in a Phase 1, open-label, uncontrolled clinical study. It was observed in the first few cases that the warts shrank and resolved without obvious necrosis, tissue damage, or inflammation. Hence, we hypothesised that somehow anti-HPV immunity was being activated. We therefore undertook morphological and histological analysis of microwave-treated human skin and investigated for evidence of enhanced anti-HPV immunity. We demonstrated that, even at low energy levels, microwave therapy potentiates cutaneous immunity to HPV.

Methods and materials

Patients and *in vivo* microwave treatment

The study was approved by the local research ethics committee in accordance with the declaration of Helsinki. Individuals with treatment-refractory plantar warts were recruited. The diagnosis of plantar wart was confirmed by a podiatrist experienced in management of such lesions. A clinically significant wart was defined as >one year duration, with at least two previous failed treatments (salicylic acid, laser, cryotherapy, needling, and surgical excision). Exclusions were pregnancy or breast feeding, pacemaker *in situ*, metal implants within the foot or ankle, co-morbidities affecting immune function, or capacity to heal. At each study visit, a complete examination of the affected area was undertaken and a quantitative measure of pain and neuromuscular function assessed. No dressing was required and volunteers continued normal everyday activities after treatment with no restrictions.

A total of 32 volunteers with 54 foot warts were enrolled into the study (17 males and 15 females; age range: 22-71 years; mean: 44.79 years [SD: 13.019]). Sixteen were solitary and 38 multiple-type warts (*e.g.* mosaic verrucae). Mean lesion duration was 60.54 months (range: 12-252) and diameter 7.43 mm (range: 2-38 mm; SD: 6.021). At the conclusion of the study period, one patient had been lost to follow-up and two patients had withdrawn ($n = 3$; four warts) but were retained in the statistical analysis, classified as unresolved lesions.

Microwave treatment (Swift[®], Emblation Medical Ltd., UK) of the most prominent plantar wart was titrated up, as tolerated to 50 J over a 7-mm diameter application area (130 J/cm²) over 5 seconds (10 watts for 5 seconds). Lesions >7 mm received multiple applications until the entire surface of the wart had been treated. If the wart persisted, treatment was repeated at one week, one month, three months, and 12 months. Response to treatment was assessed by the same investigator as binary; "resolved" or "unresolved". Resolution was indicated by fulfilling three criteria: (1) lesion no longer visible; (2) return of dermatoglyphics to the affected area; and (3) no pain on lateral compression. Pain was assessed using a 10-point visual analogue scale.

Human skin and blood samples

Skin and blood samples for microwave experiments were acquired from healthy individuals as approved by the local Research Ethics Committee in adherence to Helsinki Guidelines.

Histological analysis

Skin samples were treated immediately *ex-vivo* with microwaves (Swift s800; Emblation Ltd., UK) or liquid nitrogen therapy and punch biopsies taken from treated skin were sent for histological analysis or placed in culture media.

Histological analysis of hematoxylin and eosin (H&E)-stained tissue sections was undertaken following fixation and embedding in paraffin wax. DNA damage was assessed by staining for single-stranded and double-stranded DNA

breaks by TUNEL assay using the ApopTag[®] In Situ Apoptosis Detection Kit (Millipore, UK). Following culture, supernatants were collected and analysed for lactate dehydrogenase (LDH) release using the Cytotoxicity Detection Kit (Roche applied science) as a measure of apoptosis.

Cell culture and *in vitro* microwave treatment

Primary keratinocytes were obtained from pooled neonatal foreskin donors (Lonza, Switzerland) and cultured in keratinocyte growth medium 2 (PromoCell) at 37°C, 5% CO₂, until 70-90% confluency for use in experimental work (P4-P10).

Human skin explant cultures and human HaCaT keratinocytes were cultured in calcium-free DMEM (ThermoFisher Scientific) with 100 U/mL penicillin, 100 µg/mL streptomycin, 1 mM sodium pyruvate, 10% foetal bovine serum (FBS), and supplemented with calcium chloride at 70 µM final concentration.

Microwave treatment of cells in culture was delivered in a flat-bottomed well using the Swift device applied directly to the plastic base from the underside. To assess whether the plastic caused loss of microwave energy in our system, the 150 J Swift programme applied through the culture well base delivered a temperature rise of 18.6°C (SD: 1.1) to 200 g of culture media, equivalent to ~15.61 J (SD: 0.92). Thus, it could be estimated that 15 J applied *ex vivo* would be equivalent to ~150 J as tested here *in vivo*. However, energy loss during skin application would reduce this difference, but calculation of the precise transfer of energy to skin *in vivo* was not possible, so we estimate that the dose delivered *in vitro* is up to 10-fold lower than that by direct skin application *ex vivo*. To avoid confusion, the setting on the Swift system is the energy level referred to throughout the manuscript (in human and *in vitro* studies).

Lymphocytes were cultured in RPMI-1640 medium with 100 U/mL penicillin, 100 µg/mL streptomycin, 1 mM sodium pyruvate, and 292 µg/mL L-glutamine, supplemented with 10% FBS or 10% heat-inactivated human serum (HS). HaCaT cells were cultured to sub-confluency to avoid cell differentiation and used in assays at passage 60-70. Cells were plated at 2.5×10^3 cells/well in 96-well flat plates (Corning Costar) and cultured overnight to reach confluence. HaCaTs were washed once with PBS before treatment with microwaves, liquid nitrogen (10 seconds), or with LPS+IFN- γ (1 ng/mL+1,000 U/mL). Cells were cultured for 24 hours before supernatants were harvested. HPV16 E7 protein was expressed in *E. coli* at the Protein Core Facility of Cancer Sciences Unit, University of Southampton. Endotoxin was removed using Detoxi-Gel endotoxin removal using columns (Thermo Scientific).

For HPV-specific T cell lines, PBMCs were isolated from HLA-A2-positive individuals, as previously described [14]. PBMCs were seeded at $2-4 \times 10^6$ cells/well in 24-well culture plates and 10 µg/mL ninemer HLA-A2-restricted HPV16 epitope LLM (LLMGTLGIV) [15] was added; cells were cultured in 1 mL RPMI+10% HS. On Day 3, cells were fed with RPMI+10% HS+IL-2 (200 IU/mL), and then fed again on Day 7 or when needed. After Day 10, HPV-specific T cells were harvested for cryopreservation before testing against HPV using ELISpot assays.

To generate monocyte-derived dendritic cells (moDCs), CD14+ cells, were positively isolated from PBMCs by

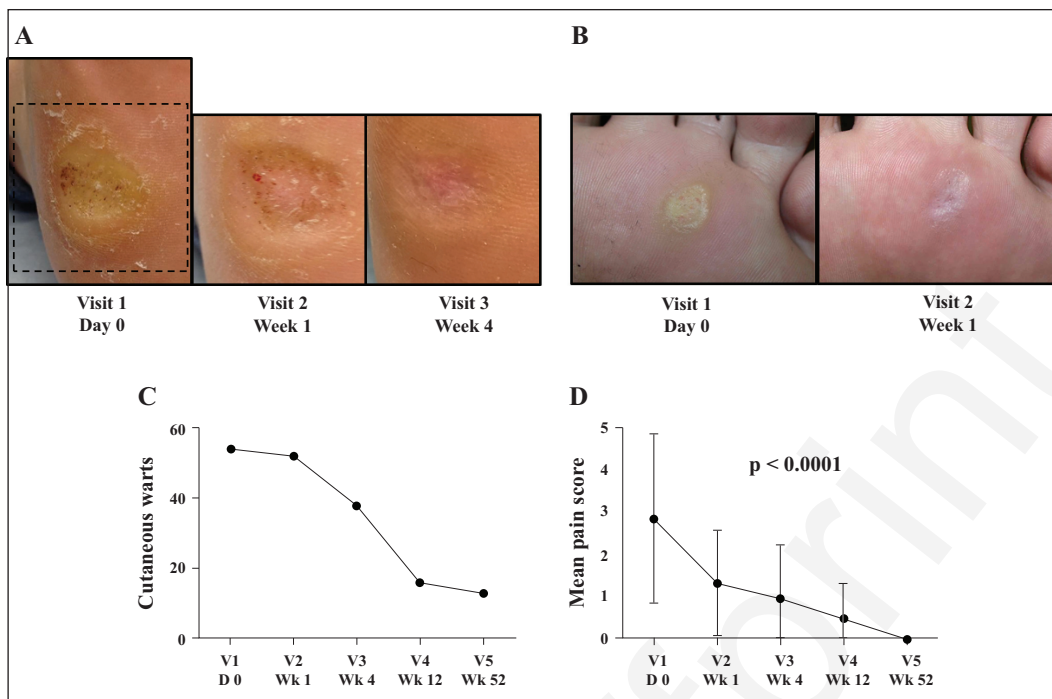


Figure 1. Response of recalcitrant warts to microwave therapy. **A)** Clinical image of plantar wart pre-microwave treatment (left), after one treatment (middle), and after two treatments (right). **B)** Clinical image of plantar wart pre-microwave treatment (left) and after one treatment (right). **C)** Intention to treat analysis of 32 patients with 54 HPV foot warts treated by microwave therapy over five visits: baseline, one week, one month, three months, and 12 months. Resolved warts were enumerated. **D)** Pain scores were assessed using a 10-point visual analogue score at each visit. Statistical test: one-way ANOVA.

magnetic separation using CD14 microbeads (Milenty Biotec, UK), according to the manufacturer's protocol. Cells were washed and resuspended in RPMI+10% FBS+250 U/mL IL-4 and 500 U/mL GM-CSF. At Day 3, cells were fed with RPMI+10% FBS+IL-4 and GM-CSF, and then harvested on Day 5 for use in functional assays.

ELISpot, flow cytometry and qPCR

Keratinocytes (HaCaTs or primary as indicated) were treated with microwaves at various energy settings before removal of supernatant at various time points. MoDCs were treated overnight with keratinocyte supernatant, then washed twice before incubation with LLM peptide (10 µg/mL for 2 hours) or HPVE7 protein (10 µg/mL for 4 hours) before a further wash. Human IFN-γ ELISpot (Mabtech, Sweden) was undertaken, as per the manufacturer's protocol and as reported previously [14]. moDCs at 1×10^3 were plated with autologous HPV peptide-specific T cells at a ratio of 1:25. Spot forming units (sfu) were enumerated with ELISpot 3.5 reader (AID, Germany). MoDCs were treated with HaCaT supernatant and harvested at 24 hours for flow cytometric analysis of cell phenotype. Cells were stained with violet LIVE/DEAD stain (Invitrogen, ThermoFisher, UK) for 30 minutes at 4°C, then washed with PBS+1% BSA and stained with antibodies PerCP-Cy5.5 anti-HLA-DR, FITC anti-CD80, FITC anti-CD86, or PE anti-CD40 (Becton Dickinson, UK) for 45 minutes at 4°C. Cells were washed, then resuspended in PBS+1% BSA, and analysed using the BD FACSAria and the FlowJo v10.0.08 analysis software.

The expression of chosen genes was validated with quantitative PCR using the TaqMan gene expression assays for target genes: *YWHAZ* (HS03044281_g1), *IRF1* (Hs00971960_m1), and *IRF4* (Hs01056533_m1) (Applied Biosystems, Life Technologies, UK) in human skin, and treated as indicated. RNA extraction (RNeasy mini kit, Qiagen) and reverse transcription (High-Capacity cDNA Reverse Transcription Kit, Applied Biosystems; ThermoFisher Scientific UK) were carried out accordingly to the manufacturer's protocol.

Results

Treatment of human papilloma virus infection in humans with microwave therapy

Of the 32 volunteers with severe warts, 54 treatment-refractory plantar warts were treated with microwave therapy (figure 1A, B). At the end of the study period, of the 54 warts treated, 41 had resolved (75.9%) and nine remained unresolved (16.7%), and two patients (with three warts [5.6%]) withdrew from the study and one patient (with one wart [1.9%]) was lost to follow-up. The mean number of days to resolution was 79.49 days (SD: 34.561; 15-151 days). Of the resolving lesions, 94% had cleared after three treatments (figure 1C). No significant difference in resolution rates between males and females ($p = 0.693$) was observed. Statistically significant reductions in pain were observed as treatment progressed ($p < 0.0001$) (figure 1D). Adverse events were minimal. One patient reported

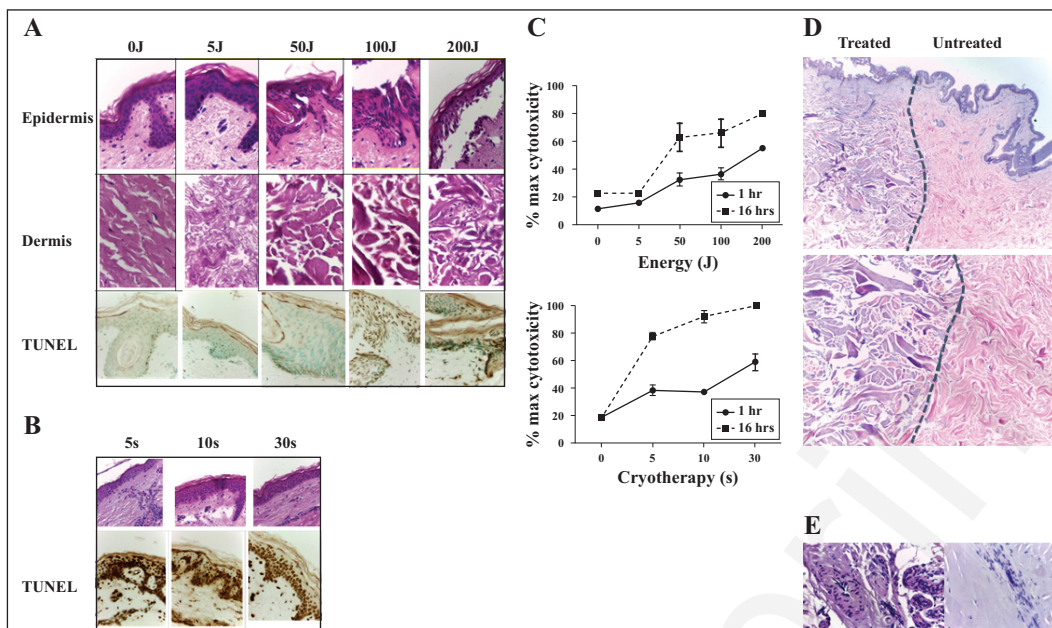


Figure 2. Microwave effects on human skin. **A)** Histological analysis of normal human skin treated with microwave stimulation visualised in the epidermis/papillary dermis (upper and lower panels), or deep dermis (middle panels). Skin was subjected to microwave therapy (0-200 J) before punch excision. Tissue was cultured for one hour before fixation and paraffin embedding (H&E or TUNEL staining; original magnification: $\times 20$). **B)** Histological analysis of human skin treated with liquid nitrogen therapy for 5, 10, or 30 seconds, before punch excision. Tissue was cultured for one hour before fixation and paraffin embedding (H&E or TUNEL staining; original magnification: $\times 20$). **C)** Following microwave therapy (upper panel) or cryotherapy (lower panel), skin samples (in triplicate) were excised and cultured in media for one or 16 hours before measurement of cytotoxicity, assessed by harvesting supernatant to measure supernatant lactate dehydrogenase (LDH) release by ELISA. **D)** Skin was subjected to microwave therapy (150 J) before punch excision at the margin of the treated zone. Tissue was cultured for one hour before fixation and paraffin embedding (H&E stain; original magnification: $\times 10$ [upper panel], $\times 100$ [lower panel]). **E)** Skin was subjected to microwave therapy (150 J) before punch excision. Tissue was cultured for one hour before fixation and paraffin embedding (H&E stain showing deep dermis adnexae: glandular [left] and vascular [right]; original magnification: $\times 100$). Data are representative of three independent experiments.

transient pain from the treatment which required a simple oral analgesic (paracetamol) and resolved within 24 hours. This individual withdrew from the study. No further adverse events were reported. No cases of scarring were recorded following completion of treatment. No cases of neuromuscular dysfunction were reported.

Microwave treatment of human skin

Human skin has not previously been reported to be treated with microwave therapy, therefore, we proceeded to undertake a full histological analysis of treated skin. Skin removed during routine surgery was treated *ex vivo* and one hour after treatment punch biopsies were taken and fixed for histological processing. Neither macroscopic nor histological changes were noted with the lowest energy setting (5 J). At 50 J, mild macroscopic epidermal changes only were noted, and microscopically minor architectural changes and slight elongation of keratinocytes were seen without evidence of altered dermal collagen. At higher energies (100/200 J), gross tissue contraction was visible macroscopically. Microscopic changes in the epidermis were prominent, showing spindled keratinocytes with linear nuclear architectural changes and subepidermal clefting (figure 2A). Dermal changes were prominent at energies of 100 J and above and showed a homogenous hyalinised zone of papillary dermal collagen, thickened collagenous sub-

stances, and accentuation of basophilic tinctorial staining of the dermal collagen with necrotic features (figure 2A). These features are similar to electro-cautery artefacts and suggest that at > 100 J, there is the potential to coagulate proteins and induce scarring. Histological analysis both at 16 hours and 45 hours showed similar changes (data not shown).

In clinical practice, cryotherapy is delivered to the skin by cryospray, which is time-regulated by the operator. In contrast to microwave therapy, minimal epidermal or dermal architectural change was identified with cryotherapy at standard treatment duration times (5-30 seconds), but did show a dose-dependent clumping of red blood cells in vessels (figure 2B).

Tissue release of LDH acts as a biomarker for cellular cytotoxicity and cytolysis. To examine the extent of cell death induced by microwave irradiation, human skin was treated with 0, 50, 100 or 200 J before punch excision of the treated area and incubation in medium for one hour or 16 hours. Measurement of LDH revealed a dose-dependent induction of tissue cytotoxicity with increasing microwave energies (figure 2C). In line with the lack of histological evidence of cellular damage, at 5 J, cytotoxicity of microwave application was equivalent to control. Early cytotoxicity was not prominent at 50 J, but became more evident after 16 hours. Higher energy levels induced more prominent cytotoxic damage. In contrast to microwave therapy, liquid nitrogen

treatment of skin induced cytotoxicity at the lowest dose both at one hour and 16 hours.

Terminal deoxynucleotidyl transferase dUTP nick end labelling (TUNEL) identifies cells in the late stage of apoptosis. Analysis at 0, 5, 50, 100 and 200 J identified increased cellular apoptosis in the epidermis above 100 J (*figure 2A*). In contrast, cryotherapy induced significant epidermal and dermal DNA fragmentation (*figure 2B*).

The physics of microwave therapy suggests a sharp boundary between treated and untreated tissue with minimal spreading of the treated field. This was borne out histologically by a clear demarcation between treated areas extending vertically from the epidermis through the dermis (*figure 2D*). Examination of the dermis showed that microwave therapy modified skin adnexae, inducing linear nuclear architectural changes in glandular apparatus, micro-thrombi, fragmented fibroblasts, and endothelial cells (*figure 2E*).

Microwave induction of immune responses in skin

We first examined the response of keratinocytes to microwave therapy *in vitro*. In analysing *in vitro* the effects of microwave therapy, it was necessary to apply the microwave treatment through culture dish plastic. Thus, the energy setting *in vitro* is equivalent to a lower energy setting than with direct application *in vivo* (*see above*). In keratinocyte monolayers (HaCaT), apoptosis was induced by microwave therapies above 100 J *in vitro* (*figure 3A*). Only above the apoptotic threshold (100 J) were surface phenotypic changes of cellular activation noted in viable cells with increased expression of HLA-DR, CD40, and CD80 (*figure 3B*). Next, we utilised a model of skin cross-talk of keratinocyte signalling to dermal dendritic cells. Initially, we observed strong activation of MoDCs primed with supernatant from microwave-treated keratinocytes (*data not shown*), but we wished to disentangle the pro-inflammatory effects of apoptosing/necrotic cells from viable cell cross-talk. Therefore, keratinocytes were treated with microwave therapy as above, and washed after eight hours to remove dead or apoptotic cells. Treated keratinocytes were then incubated for a further 16 hours before supernatant collection to prime moDCs, which had not been directly exposed to microwave therapy. The supernatants induced potent induction of moDC activation with increased expression of CD86, CD80, and to a lesser extent, CD40 (*figure 3C*).

We next set out to model the functional outcome on skin dendritic cells following microwave treatment of keratinocytes. Keratinocyte monolayers (HaCaT) were untreated, or microwave- or cryotherapy treated before supernatant harvesting. Supernatant-primed DCs were pulsed with a nine-amino acid HLA-A2 epitope (LLM) from human papilloma virus (HPV) E7 protein and cultured with an autologous HPV-specific CD8+ T cell line. As expected, in all conditions, the moDCs efficiently presented HPV peptide to HPV-specific CD8+ T cells, inducing IFN γ (*figure 4A*). However, dendritic cell presentation of HPV is dependent upon cross-presentation to the MHC class I pathway. Therefore, we also tested the capability of untreated, microwave-treated or cryotherapy-treated KC-primed moDCs to present HPV E7 protein to

an HLA-matched HPV-specific CD8+ T cell line. Strikingly, only microwave-treated KCs were capable of priming moDCs to enhance cross-presentation (*figure 4B*). To explore the potential mechanism of keratinocyte response to microwave therapy, we confirmed up-regulation of HSP-70 in response to microwave therapy of keratinocytes (*figure 4C*). Although, the assay used did not distinguish constitutive from inducible HSP-70, we clearly demonstrated global increase in HSP-70 expression following microwave therapy. Additionally, IL-6, but not IL-1 β or TNF- α , was expressed in response to microwave stimulation, which suggests that alternative inflammatory signalling pathways from that seen in cryotherapy-treated cells are induced by microwave stimulation (*figure 4D*). To further explore the potential innate immune signalling pathways in keratinocytes following microwave therapy, we examined IRF1 and IRF4. These transcription factors are key regulators of dendritic cell activation of adaptive immunity. We show that microwave therapy induced down-regulation of IRF1 and up-regulation of IRF4 (*figure 4E*).

Discussion

This is the first study to investigate the potential efficacy of locally delivered microwaves in the treatment of cutaneous viral warts. In this uncontrolled pilot study, we report a complete resolution rate of 75.9% of recalcitrant plantar warts (with an average lesion duration of over five years). This compares very well with previous reports of plantar wart resolution for salicylic acid and or cryotherapy (23-33%) [16].

For all novel therapies, adverse events are critical but we did not identify a strong signal for adverse events. As with current physical treatments for warts, discomfort is expected for the patient. During the study, patients generally reported that for a typical five-second treatment, they endured moderate discomfort for approximately two seconds, which immediately diminished after the treatment had completed. In addition, it was commonly noted that discomfort was less with subsequent treatments. One male patient withdrew from the study after one treatment, citing the pain of treatment as the reason. In the study design phase, pre-operative use of topical anaesthetic cream was tested, but appeared to do little to mitigate the pain (*unpublished data*) and it was felt that the pain of local anaesthetic injection would exceed that normally experienced during a microwave treatment. Following microwave therapy, patients did not require dressings or special advice as no wound or ulcer was caused, allowing the patient to continue normal activity. The short microwave treatment time (five seconds) offers a significant clinical advantage over current wart therapies, such as cryotherapy and electro-surgery. Within five seconds, microwaves penetrate to a depth of over 3.5 mm at the energy levels adopted for the study [17]; possibly a greater depth than can be attained by cryosurgery or laser energy devices. Moreover, microwaves, like all forms of electro-magnetic radiation, travel in straight lines and energy is deposited in alignment with the "beam" emitted from the device tip with little lateral spread, meaning minimal damage to surrounding tissue, as confirmed in this study. Microwaves induce dielectric heating. When water, a polar molecule, is exposed to microwave energy, the

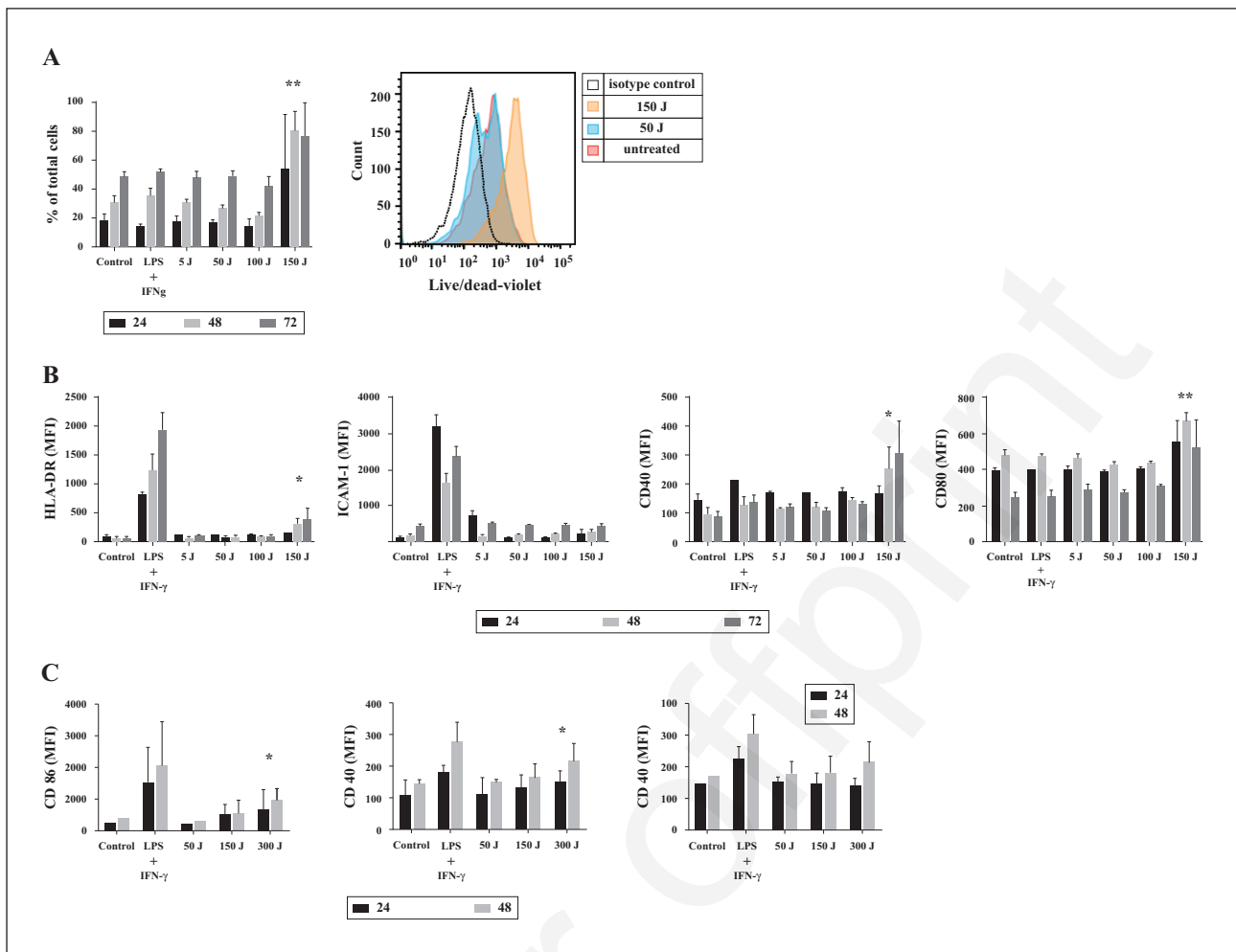


Figure 3. Microwave activation of keratinocytes and dendritic cells. **A)** Left: flow cytometric analysis of viable keratinocytes (% of total cells) indicated by negative staining with the amine reactive viability dye LIVE/DEAD after control, microwave (5-150 J), or LPS/IFN- γ treatment. Keratinocytes were treated then kept in culture for 24 (black bars), 48 (light grey) or 72 (dark grey) hours before analysis. Right: flow cytometric analysis of keratinocyte viability after microwave therapy or control, depicted as a histogram. X-axis: LIVE/DEAD stain; y-axis: cell count. **B)** Flow cytometric analysis of HLA-DR, ICAM-1, CD40 or CD80 expression on viable keratinocytes. Keratinocytes were treated with microwave therapy (5-150 J), LPS/IFN- γ , or nil (control), rested in culture for 24 (black bars), 48 (light grey) or 72 (dark grey) hours, before analysis of the viable population. **C)** Flow cytometric analysis of CD86, CD80, and CD40 expression on viable monocyte-derived dendritic cells (moDCs). Keratinocytes were treated with microwaves (5-150 J), LPS/IFN- γ , or untreated (control), rested in culture for eight hours, then washed. They were left in culture for the remaining time until 24 (black bars) or 48 (light grey) hours, before transfer of supernatant onto moDCs. MoDCs were incubated for 24 hours before harvesting for analysis. Data are representative of three independent experiments. Mean+SD; * $p < 0.05$; ** $p < 0.01$; *** $p < 0.001$.

molecule is excited and rotates to align with the alternating electro-magnetic field. At microwave frequencies, the molecule is unable to align fully with the continuously shifting field resulting in heat generation. Within tissues, this acts to rapidly elevate temperatures. This process increases cellular temperature because it does not depend on tissue conduction. Microwave treatment produces no vapour or smoke unlike ablative lasers and electro-surgery, eliminating the need for air extraction systems due to the risk of spreading viral particles within the plume [18]. Although microwave therapy has been considered a tissue ablation tool, we observed minimal skin damage after treatment with 50 J, yet good clinical responses were seen. Therefore, we investigated whether there was evidence to support an induction of anti-HPV immunity by

microwave therapy. The critical nature of CD8+ T cell immunity for host defence against HPV skin infection is well established and supported by the observation of increased prevalence of infection in immunosuppressed organ-transplant recipients [19], and that induction of protection from HPV vaccines is mediated by CD8+ T cells [20]. We show here that microwave therapy of skin induces keratinocyte activation and cell death through apoptosis. However, *in vitro* microwave-primed keratinocytes are capable of signalling to dendritic cells and enhancing cross-presentation of HPV antigens to CD8+ lymphocytes at microwave energy levels equivalent to or lower than that used in the clinical study, which offers a potential explanation for the observed response rate in our clinical study. *In vitro* evidence suggests that this is likely

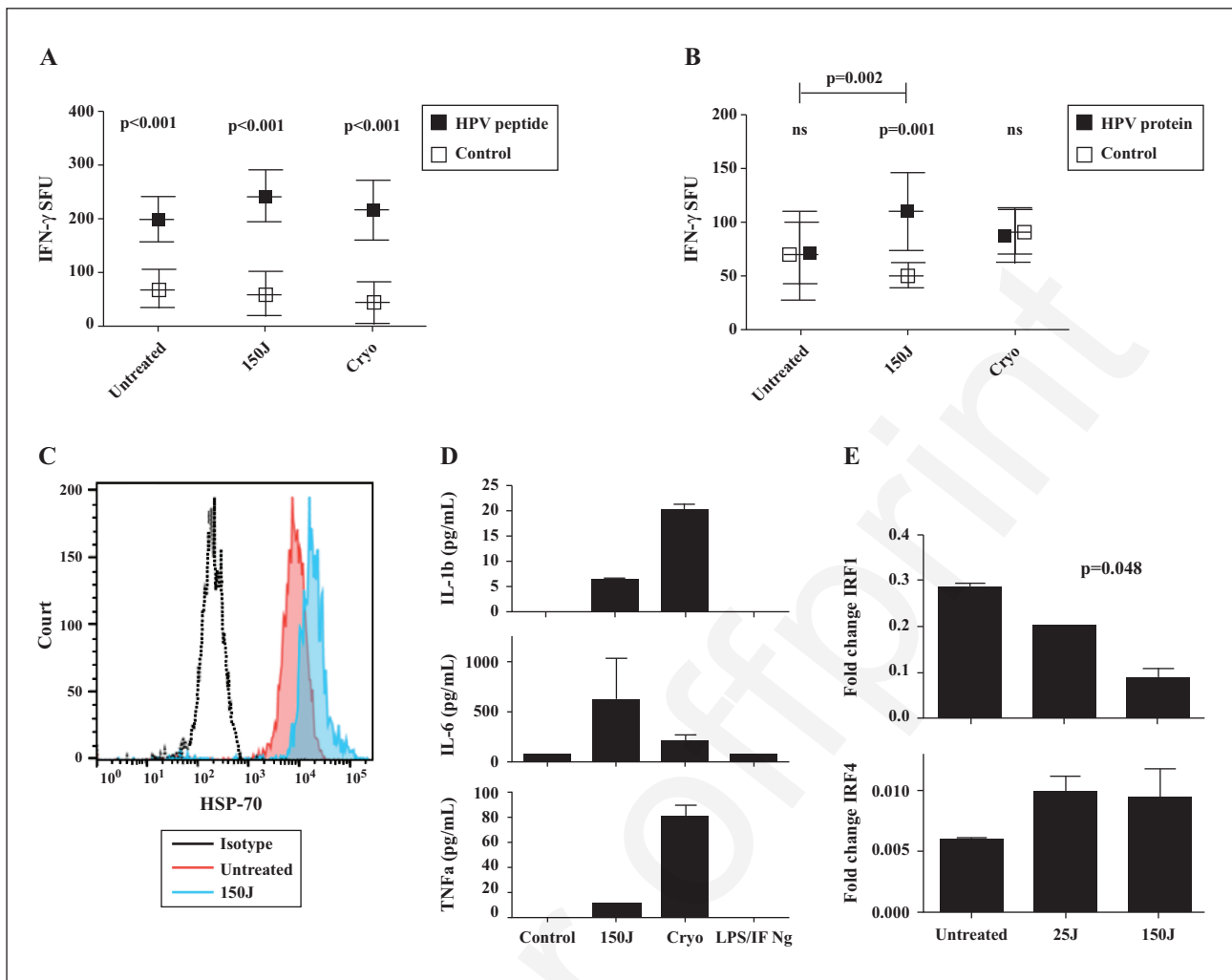


Figure 4. Microwave induction of HPV antigen cross-presentation. **A**) ELISpot assay of IFN- γ production by HPV-specific CD8+ cells following co-culture with HPV peptide-pulsed moDCs primed by supernatant from untreated, microwave-treated (150 J) or cryotherapy (cryo)-treated HaCaT keratinocytes. MoDCs were primed with supernatant for 24 hours prior to pulsing with control (open squares) or HPV peptide (closed squares) for two hours. Pulsed moDCs were then co-cultured with an HLA-matched CD8+ HPV-specific T cell line before assay with IFN- γ ELISpot. Statistical significance was determined using the Holm-Sidak method, with $\alpha = 5\%$. Data are representative of three independent experiments (mean+SD). **B**) ELISpot assay of IFN- γ production by HPV-specific CD8+ cells following co-culture with HPV E16 protein-pulsed moDCs primed by supernatant from untreated, microwave-treated (150 J) or cryotherapy (cryo)-treated HaCaT keratinocytes. MoDCs were primed with supernatant for 24 hours prior to pulsing with control (open squares) or HPV protein (closed squares) for two hours. Pulsed moDCs were then co-cultured with an HLA-matched CD8+ HPV-specific T cell line before assay with IFN- γ ELISpot. Statistical significance was determined using the Holm-Sidak method, with $\alpha = 5\%$. Data are representative of three independent experiments (mean+SD). **C**) Flow cytometric analysis of intracellular HSP-70 expression on viable keratinocytes after microwave therapy or control, depicted as a histogram. Primary human keratinocytes were treated with microwave therapy (150 J), or nil (untreated), rested in culture for 24 hours, before analysis. X-axis: anti-HSP-70; y-axis: cell count. **D**) ELISA of IL-6, TNF α , and IL-1 β production by primary human keratinocytes 24 hours after treatment with microwave therapy (150 J), LPS/IFN γ , cryotherapy or control (untreated). **E**) Fold expression of change of IRF1 and IRF4 over a housekeeping gene in normal human skin with microwave therapy (25 J and 150 J) by qPCR.

to be mediated by cross-talk between microwave-treated skin keratinocytes and dendritic cells, through induction of danger-associated molecular patterns (DAMPs), such as HSP-70 in keratinocytes, resulting in up-regulation of DC CD40 and CD80/86 and subsequent enhanced cross-presentation of HPV proteins to CD8+ T cells. Microwave therapy also specifically induced enhanced IL-6 synthesis from keratinocytes. IL-6, is a pro-inflammatory mediator, important in anti-viral immunity, which has been recently

shown to induce rapid effector function in CD8+ cells [21]. Thus, IL-6 up-regulation may provide an important additional mechanism for microwave-induced anti-viral immunity. The intriguing contrast between cryotherapy and microwave therapy revealed a far greater release of IL-1 β and TNF- α with cryotherapy which, in addition to the lesser IL-6 induction, may offer potential to utilise the treatments for different situations where IL-1 β /TNF- α -driven inflammation may be preferable, or vice versa.

Additionally, the specificity of inflammatory pathways induced by each modality may explain why cryotherapy and microwave stimulation may not show equal effectiveness in the same disease.

IRFs have been shown to be central to the regulation of immune responses [22-24]. IRF4 is essential for differentiation of cytotoxic CD8+ T cells [25, 26], but up-regulation in dendritic cells has also been shown to enhance CD4+ differentiation [23], therefore, this pathway may potentially enhance both CD8+ immunity and T-cell help following microwave treatment. IRF1 expression has been previously reported to be modulated by HPV infection, but different models have shown opposite outcomes [27, 28]. We show down-regulation of IRF1 in human skin in association with a microwave therapy, which supports the proposal of IRF-1 as a therapeutic target in HPV infection [28].

This study is the first of its kind to study microwaves in the treatment of plantar warts *in vivo*. Further work to examine the immune infiltrate in microwave-treated warts is planned. Whilst we acknowledge the limitations of the uncontrolled, non-randomised design, the promising results shown here suggest that a randomised controlled study with a larger sample size is warranted to confirm the efficacy of this treatment. ■

Disclosure. *Financial support: All financial support was provided by an investigator-led research grant from Emblation Medical Ltd., the maker of the Swift microwave system used in this study. Emblation Medical Ltd. had no input into the design, data capture, analysis, or manuscript preparation. After completion of the work and following the first draft of the manuscript, I.B. has become a consultant for Emblation Medical Ltd. Conflict of interest: none.*

References

1. Cockayne S, Hewitt C, Hicks K, *et al.* Cryotherapy versus salicylic acid for the treatment of plantar warts (verrucae): a randomised controlled trial. *BMJ* 2011; 342: d3271.
2. Kwok CS, Gibbs S, Bennett C, Holland R, Abbott R. Topical treatments for cutaneous warts. *Cochrane Database Syst Rev* 2012; 9: CD001781.
3. Riddel C, Rashid R, Thomas V. Ungual and periungual human papillomavirus-associated squamous cell carcinoma: a review. *J Am Acad Dermatol* 2011; 64: 1147-53.
4. Stern PL. Immune control of human papillomavirus (HPV) associated anogenital disease and potential for vaccination. *J Clin Virol* 2005; 32: S72-81.
5. Soong RS, Song L, Trieu J, *et al.* Toll-like receptor agonist imiquimod facilitates antigen-specific CD8+ T-cell accumulation in the genital tract leading to tumor control through IFN γ . *Clin Cancer Res* 2014; 20: 5456-67.
6. Edwards L, Ferenczy A, Eron L, *et al.* Self-administered topical 5% imiquimod cream for external anogenital warts. HPV Study Group. *Human PapillomaVirus. Arch Dermatol* 1998; 134: 25-30.
7. Bristow I, Walker N. Pulsed dye laser for the treatment of plantar warts - two case studies. *Foot* 1997; 7: 229-30.
8. Kimura U, Takeuchi K, Kinoshita A, Takamori K, Suga Y. Long-pulsed 1064-nm neodymium:yttrium-aluminum-garnet laser treatment for refractory warts on hands and feet. *J Dermatol* 2014; 41: 252-7.
9. Park H, Choi W. Pulsed dye laser treatment for viral warts: a study of 120 patients. *J Dermatol* 2008; 35: 491-8.
10. Tosti A, Piraccini BM. Warts of the nail unit: surgical and nonsurgical approaches. *Dermatol Surg* 2001; 27: 235-9.
11. Sterling JC, Gibbs S, Haque Hussain SS, Mohd Mustapa MF, Handfield-Jones SE. British Association of Dermatologists' guidelines for the management of cutaneous warts 2014. *Br J Dermatol* 2014; 171: 696-712.
12. Kwok CS, Holland R, Gibbs S. Efficacy of topical treatments for cutaneous warts: a meta-analysis and pooled analysis of randomized controlled trials. *Br J Dermatol* 2011; 165: 233-46.
13. Lloyd DM, Lau KN, Welsh F, *et al.* International multicentre prospective study on microwave ablation of liver tumours: preliminary results. *HPB (Oxford)* 2011; 13: 579-85.
14. Polak ME, Thirdborough SM, Ung CY, *et al.* Distinct molecular signature of human skin Langerhans cells denotes critical differences in cutaneous dendritic cell immune regulation. *J Invest Dermatol* 2014; 134: 695-703.
15. Rensing ME, de Jong JH, Brandt RM, *et al.* Differential binding of viral peptides to HLA-A2 alleles. Implications for human papillomavirus type 16 E7 peptide-based vaccination against cervical carcinoma. *Eur J Immunol* 1999; 29: 1292-303.
16. Bruggink SC, Gussekloo J, Berger MY, *et al.* Cryotherapy with liquid nitrogen versus topical salicylic acid application for cutaneous warts in primary care: randomized controlled trial. *CMAJ* 2010; 182: 1624-30.
17. Emblation Medical Limited. Swift applicator instructions for use. Alloa, Scotland 2012.
18. Karsai S, Daschlein G. Smoking guns": Hazards generated by laser and electrocautery smoke. *J Disch Dermatol Ges* 2012; 10: 633-6.
19. Tan HH, Goh CL. Viral infections affecting the skin in organ transplant recipients: epidemiology and current management strategies. *Am J Clin Dermatol* 2006; 7: 13-29.
20. de Jong A, O'Neill T, Khan AY, *et al.* Enhancement of human papillomavirus (HPV) type 16 E6 and E7-specific T-cell immunity in healthy volunteers through vaccination with TA-CIN, an HPV16 L2E7E6 fusion protein vaccine. *Vaccine* 2002; 20: 3456-64.
21. Bottcher JP, Schanz O, Garbers C, *et al.* IL-6 trans-signaling-dependent rapid development of cytotoxic CD8+ T cell function. *Cell Rep* 2014; 8: 1318-27.
22. Schlitzer A, McGovern N, Teo P, *et al.* IRF4 transcription factor-dependent CD11b+ dendritic cells in human and mouse control mucosal IL-17 cytokine responses. *Immunity* 2013; 38: 970-83.
23. Vander Lugt B, Khan AA, Hackney JA, *et al.* Transcriptional programming of dendritic cells for enhanced MHC class II antigen presentation. *Nat Immunol* 2013; 15: 161-7.
24. Tussiwand R, Lee WL, Murphy TL, *et al.* Compensatory dendritic cell development mediated by BATF-IRF interactions. *Nature* 2012; 490: 502-7.
25. Huber M, Lohoff M. IRF4 at the crossroads of effector T-cell fate decision. *Eur J Immunol* 2014; 44: 1886-95.
26. Raczkowski F, Ritter J, Heesch K, *et al.* The transcription factor interferon regulatory factor 4 is required for the generation of protective effector CD8+ T cells. *Proc Natl Acad Sci USA* 2013; 110: 15019-24.
27. Park JS, Kim EJ, Kwon HJ, Hwang ES, Namkoong SE, Um SJ. Inactivation of interferon regulatory factor-1 tumor suppressor protein by HPV E7 oncoprotein. Implication for the E7-mediated immune evasion mechanism in cervical carcinogenesis. *J Biol Chem* 2000; 275: 6764-9.
28. Muto V, Stellacci E, Lamberti AG, *et al.* Human papillomavirus type 16 E5 protein induces expression of beta interferon through interferon regulatory factor 1 in human keratinocytes. *J Virol* 2011; 85: 5070-80.

Treating verrucae effectively with microwave energy – are we getting warmer?

Ivan Bristow¹ & Michael Ardern-Jones²

Faculty of Health Sciences¹ & Faculty of Medicine²

University of Southampton, UK

“Those who cannot be cured by medicine can be cured by surgery. Those who cannot be cured by surgery can be cured by heat. Those who cannot be cured by heat are to be considered incurable”.

Hippocrates

The treatment of cutaneous warts has not significantly changed in decades. In 2000, Dyall-Smith [1] remarked how little verruca treatments had changed since the fifties and this still holds true today - perhaps with the additions of some newer topical antiviral drugs [2] and photodynamic therapies [3]. Over the years, podiatric training for the treatment of warts is still largely based on chemical means including salicylic acid, monochloroacetic acid, trichloroacetic acid and liquid nitrogen as cryotherapy.

Looking at the evidence for these modalities, years on, it doesn't make for particularly good reading. The latest guidelines published by the British Association of Dermatologists [4] in 2014 continues to closely review the common remedies such as salicylic acid and liquid nitrogen. Although success is reported as being “modest” in most cases it offers a disappointing outlook for sufferers. Particularly notable is the lower response rates from plantar warts. Salicylic acid treatment has better outcomes than placebo and response rates for both cryotherapy and salicylic acid are just over 30%. Moreover, the science explaining how they may work is lacking.

Cryotherapy, like the chemical therapies, is something which has been taught for many years in podiatry as an established treatment for plantar warts. In the latest review by Sterling, it suggests how its effects are at best limited. Moreover, the likelihood of prolonged pain and blistering is always a possibility particularly when longer freeze times have been applied. It is this unpredictability which perhaps has resulted in its decline in every podiatric practice. Cryotherapy, like the rest, is a

reasonable treatment for warts but unfortunately not on the sole of the foot. Keratin is an excellent insulator, reducing the penetration of the cold temperatures and thereby protecting the underlying skin and virus from frost damage.

In 2015, the authors undertook a study using microwave as a treatment for plantar warts. This was an emerging technology which had been developed over several years. The use of this device switched from the cold treatment of liquid nitrogen to that of localised tissue heating utilising dielectric energy. Microwaves when applied to human tissue have the ability to agitate water molecules. As a polar molecule, water attempts to align with the electrical field but because of the oscillating frequency is in constant movement they are unable to rest. This effect causes the molecule to rotate rapidly and generate heat at a molecular level within the tissues.

The work from this clinical study of the device, conducted through the University of Southampton, demonstrated that this technique was capable of eradicating stubborn warts and it has now been adopted more widely into clinical practice. Logically, the next question to explore is what are the microwaves actually doing? How does it work against this viral infection of the epidermis?

Microwaves easily travel through tissues, unlike heat energy from an infra-red source, such as a cautery device, where heat is transmitted by conductance. In contrast to carbon dioxide laser, for example, energy levels delivered by the Swift microwave device (Emblation Medical Limited, Alloa) are low and not designed to be ablative in nature so there is no tissue vaporisation hence no smoke, steam or burn. The temperature is raised to a level which is termed as “heat shock” in the range 41° to 44° C compared to normal body temperature (37°). At this hyperthermia level the increase in temperature has several effects - hyperthermia is widely acknowledged to provide an anti-tumour response through [5]:

1. Heat dissipation – tumours are more compact and disorganised and so cannot dissipate heat as readily as normal tissue and so are more sensitive to heating.
2. Tissue damage or death (apoptosis) to cell membranes and intra-cellular structures.
3. Modulation of a number of immune processes.

It is this latter point which potentially holds the key to new developments in treatment. Studies have highlighted successful eradication of tumours treated with temperatures in the heat shock temperature range [6]. More specifically, heating has been used to successfully eradicate warts. Huo and colleagues [7] undertook a randomised controlled trial of 54 patients to assess how repeated heating of warts to 44° C affected resolution. At the end of the study 54% of the treated group had resolved versus just 12% in the placebo arm. This work also reported that treatment of a single “target” lesion could promote an immune response that cleared all lesions resulting in a more tolerable treatment. A downside to this proposed heating treatment regimen which employed infrared energy was the use of 30-minute treatment cycles which clinically may not be practical.

For normal adaptive immunity to occur in the skin, virally infected tissue has to be taken up by skin dendritic cells and carried to the lymph nodes for priming of CD8+ T cells. Primed T cells, migrate from the lymph node and recirculate to the skin where they can then recognise and kill HPV infected skin cells. Warts on the skin are well known for their persistence, suggesting that host immunity is imperfect in dealing with this infection. A variety of well-established mechanisms for host immune evasion exist, including down regulation of antigen processing machinery, and impaired dendritic cell function [8]. For example, previous work has demonstrated that during HPV skin infection, upregulation of the PI3-K pathway suppresses anti-HPV responses in Langerhans cells. Inhibition of this pathway, increased anti-HPV activity leading to rapid clearance of HPV [8]. Heating skin has been shown to enhance Langerhans cell migration from the epidermis [9] and additionally, it has been shown that by heating tissue, increased temperatures may exert an effect by preventing PI3-K activation thereby potentiating the immune recognition of HPV infection [10].

If tissue is exposed to temperatures above 41° centigrade, cell damage and death is likely however, cells under stress (such as heating) produce chemicals known as Heat Shock Proteins (HSP). These have evolved to protect cells in extreme stress conditions from cell death. HSP's have a number of functions - as protein chaperones that are involved with the folding, shape regulation and degradation of intracellular proteins [11]. However, their effects on the immune system are of more interest. HSP-70 has been shown to induce the maturation of Langerhans cells and enhance their migration to the lymph nodes. When comparing normal skin to HPV infected skin, it was discovered that the migratory response was more marked in the HPV infected skin [12]. HSP release also has been shown to stimulate cytokine release from antigen presenting cells, as well as nitric oxide, chemotactic factors from macrophages and to stimulate anti-tumour responses [5].

Other work has discovered that when HPV infected cells are heated, there is a greater release of the natural anti-viral group of cytokines known as interferons. In a study by Zhu et al. [13], they compared the release of interferons by heating virally infected human cells versus uninfected cells and demonstrated that HPV infected skin when exposed to 42°-45° degrees produced larger quantities than uninfected tissue. Interferons are important cell signals which promote immune function. It has also been demonstrated that during hyperthermally induced wart regression, a high level of CD4+ and CD8+ T lymphocyte infiltration was identified in the treated areas suggesting that cellular recruitment is enhanced by heat induced epithelial damage, which is likely to be central to anti-viral immune responses [14].

The above work, has demonstrated how research into hyperthermia has shown some positive insights into how raising skin temperature into the 41° – 45° range can bring about cellular changes conducive to resolution but, is there any evidence that such effects are induced by microwave heating? We have previously reported a study of human skin explant sections were subjected to treatment using the Swift Microwave device and liquid nitrogen to observe for anti-HPV immune activity. Skin keratinocytes normally reside in a non-activated state. However, those from microwave-treated human skin were found to show increased expression of HSP-70 and were able to signal to dendritic cells. Even at a low energy, keratinocyte induced dendritic cell activation induced enhanced cross-presentation of HPV antigens to CD8+ T cells with consequent interferon- γ production [15]. Interestingly, in liquid nitrogen treated control experiments, similar keratinocyte driven dendritic cell activation was not found.

Most recently the authors demonstrated that microwave treatment of cutaneous warts can be effective. In the first study of its kind, a cohort of 32 adults with refractory warts were treated with a course of microwave therapy using the Swift® device. At the conclusion, the resolution rate was 75.9% with 41 of the 54 warts reported as resolved [16].

Taken together, the basic science of microwave effects on skin and clinical responses noted suggest a mechanism for the observed action of microwaves in cutaneous warts, although more research is required to further this knowledge. Our understanding of the molecular mechanisms of hyperthermia provides a strong case for this new technology to be explored further as a local immune response

activator therapy. Additionally, it seems likely that there may be many other potential dermatology applications for this exciting technology.

References

1. Dyll-Smith DJ: **Treatment of warts at the turn of the millennium.** *Australas J Dermatol* 2000, **41**(s1):S20-S22.
2. Bonatti H, Aigner F, De Clercq E, Boesmueller C, Widschwendner A, Larcher C, Margreiter R, Schneeberger S: **Local administration of cidofovir for human papilloma virus associated skin lesions in transplant recipients.** *Transpl Int* 2007, **20**(3):238-246.
3. Vogel S, Ruzicka T, Berking C: **Subluminescence photodynamic therapy of recalcitrant foot warts.** *Br J Dermatol* 2015:early view online.
4. Sterling JC, Gibbs S, Haque Hussain SS, Mohd Mustapa MF, Handfield-Jones SE: **British Association of Dermatologists' guidelines for the management of cutaneous warts 2014.** *Br J Dermatol* 2014, **171**(4):696-712.
5. Hegyi G, Szigeti GP: **Hyperthermia versus Oncothermia: Cellular Effects in Complementary Cancer Therapy.** *Evid Based Complement Alternat Med* 2013, **2013**:12.
6. Wust P, Hildebrandt B, Sreenivasa G, Rau B, Gellermann J, Riess H, Felix R, Schlag PM: **Hyperthermia in combined treatment of cancer.** *Lancet Oncol* 2002, **3**(8):487-497.
7. Huo W, Gao XH, Sun XP, Qi RQ, Hong Y, McHepange UO, Li XD, Xiao BH, Lin JP, Jiang Y *et al*: **Local hyperthermia at 44 degrees C for the treatment of plantar warts: a randomized, patient-blinded, placebo-controlled trial.** *J Infect Dis* 2010, **201**(8):1169-1172.
8. Fausch SC, Fahey LM, Da Silva DM, Kast WM: **Human papillomavirus can escape immune recognition through Langerhans cell phosphoinositide 3-kinase activation.** *J Immunol* 2005, **174**(11):7172-7178.
9. Ostberg JR, Kabingu E, Repasky EA: **Thermal regulation of dendritic cell activation and migration from skin explants.** *Int J Hyperthermia* 2003, **19**(5):520-533.
10. Choi M, Salanova B, Rolle S, Wellner M, Schneider W, Luft FC, Kettritz R: **Short-term heat exposure inhibits inflammation by abrogating recruitment of and nuclear factor- κ B activation in neutrophils exposed to chemotactic cytokines.** *Am J Pathol* 2008, **172**(2):367-777.
11. Bukau B, Horwich A: **The HSP70 and HSP60 chaperone machines.** *Cell* 1998, **92**(351-366).
12. Li X, Gao XH, Jin L, Wang Y, Hong Y, McHepange UO, Wang X, Jiang Y, Wei H, Chen HD: **Local hyperthermia could induce migrational maturation of Langerhans cells in condyloma acuminatum.** *J Dermatol Sci* 2009, **54**(2):121-123.
13. Zhu L-I, Gao X-H, Qi R, Hong Y, Li X, Wang X, McHepange UO, Zhang L, Wei H, Chen H-D: **Local hyperthermia could induce antiviral activity by endogenous interferon-dependent pathway in condyloma acuminata.** *Antiviral Res* 2010, **88**(2):187-192.
14. Huo W, Di ZH, Xiao BH, Qi RQ, Weiland M, Gao XH: **Clearance of genital warts in pregnant women by mild local hyperthermia: a pilot report.** *Dermatologic Therapy* 2014, **27**(2):109-112.
15. Ardern-Jones M, Lee A, Chean LW, Holbrook D, Savelyeva N, Thomson P, Webb C, Polak ME, Bristow IR: **Induction of antihuman papillomavirus immunity by microwave treatment of skin.** *Br J Dermatol* 2016, **175**(Supp 1):151.

16. Bristow IR, Lim W, Lee A, Holbrook D, Savelyeva N, Thomson P, Webb C, Polak ME, Ardern-Jones MR: **Microwave therapy for cutaneous human papilloma virus infection.** *Eur J Dermatol* 2017:(in press).

Single Case

The Successful Use of a Novel Microwave Device in the Treatment of a Plantar Wart

Ivan Robert Bristow^a Christopher Webb^b
Michael Roger Ardern-Jones^{c, d}

^aFaculty of Health Sciences, University of Southampton, Southampton, UK;

^bThe Podiatry Centre, Portsmouth, UK; ^cFaculty of Medicine, University of Southampton, Southampton, UK; ^dDepartment of Dermatology, University Hospitals Southampton NHS Foundation Trust, Southampton, UK

Keywords

Warts · Verrucae · Treatment · Infections · Microwave · Human papilloma virus

Abstract

Plantar warts, caused by the human papilloma virus (HPV), are a commonly encountered condition presenting in clinic. In adults, an array of various therapies exists, frequently with modest results particularly with plantar lesions. Microwaves have had limited uses for medical purposes. Recently a new portable microwave device has been approved for the treatment of skin lesions. Prior research has demonstrated immuno-stimulatory effects against HPV infection. We report the application of a novel portable medical microwave unit to treat a long-standing plantar wart which had failed to respond to other treatment modalities.

© 2017 The Author(s)
Published by S. Karger AG, Basel

Introduction

Cutaneous warts are a common clinical problem estimated to affect between 7 and 12% of the population [1]. For many younger patients, natural resolution is a common feature, but in adults they often remain stubborn and refractory to treatment. As highlighted in re-

cent guidelines, long-term persistence and failure to respond to therapy are more commonly features of cutaneous warts located on the plantar area of the foot [2]. In addition to the low success rate of common therapies such as salicylic acid and cryosurgery for warts in this location, these therapies cause local irritation and pain making their use unfavourable [2].

Case Report

A 41-year-old male with a stubborn, single plantar wart on his right styloid process which had been present for over a year and had failed to respond to treatment with cryosurgery (Fig. 1). The lesion was described as painful when standing. The lesion measured 10 by 10 mm, and the patient rated the pain level as an 8 out of 10 (numeric rating scale) at the initial assessment. He had no significant past medical or medication history. Following a discussion with the patient about the various options available, the patient consented for treatment using microwave energy. After gentle reduction of the hyperkeratotic skin overlying the lesion, microwave energy was applied using the Swift S800 Microwave Device (Emblation Medical Ltd, Alloa, UK). Device settings were programmed to deliver 50 J (10 W for 5 s). Microwaves were delivered without topical or local anaesthetic to the verruca through an applicator applied directly onto the surface of the lesion. After intervention, no dressing was required, and the patient was able to mobilise freely. After 3 weeks, the patient was reviewed. The treated area demonstrated large amounts of bruising (Fig. 2). Pain measurement was recorded as 2 out of 10 (NRS), corresponding to a 75% improvement compared to pre-operative levels. Interestingly, the patient noted that pain had reduced almost immediately following the first microwave ablation. A second treatment of 50 J was administered to the same area under the same settings. Two weeks later, the lesion was almost completely resolved (Fig. 3) and pain score assessment was 0 out of 10 (NRS). At 6-month follow-up, the lesion remained fully resolved (Fig. 4).

Discussion

This case represents a report of successful treatment of a cutaneous wart using a portable microwave therapy device. The device was developed and subsequently “CE” marked as a medical device for the general indications “in the treatment and ablation of skin lesions.” In this singular case presentation, the microwave device proved successful and creates a pathway for further research into the treatment of plantar warts. Microwaves are a type of non-ionising radiation in the 300 MHz to 300 GHz wavelength range of the electro-magnetic spectrum. Application to the skin works on the principle of dielectric heating. Polar molecules, such as water, when exposed to microwave energy, rotate and attempt to align with the changing electro-magnetic field. At microwave frequencies, rapidly rotating molecules generate heat which is dissipated to the surrounding tissues and acts to rapidly elevate temperatures. To date, the medical applications of microwaves have been relatively limited and not widely explored. The technology has been successfully utilised intra-operatively to ablate large tumours [3, 4] but little work has focused on its applications in the treatment of skin lesions. The unit produces microwave energy within the 8 GHz range from an internal generator, delivered through a cable into a ceramic cap, directly into the tissues to which it is applied. The applicator tip of the device is single use reducing the risk of cross-infection. The physical properties of microwaves potentially offer significant advantages over cryotherapy

and laser modalities when used medically on the skin. Firstly, as microwaves travel through tissue in straight lines in alignment with the device tip, there is minimal lateral spread of heat, meaning minimal damage to surrounding tissue. Moreover, microwave energy is not dependent on tissue conductivity, and tissue effects can therefore be produced much more rapidly than with cryotherapy cooling. Compared to laser light, microwaves are not modified by chromophores, and therefore microwaves show a greater depth of penetration into the skin. At powers of up to 10 W, a penetration of up to 3 mm can be expected. An additional advantage is that the procedure does not induce vapour, smoke or particulate debris, which is a common problem with high energy lasers, and has been reported to spread viral particles within the plume [5]. Additionally, the device causes no skin breakage at site of application (at this energy setting) and so did not require any post-operative dressing, allowing the patient continue normally activity. The benefits of a heat therapy over a cold treatment such as liquid nitrogen application can be seen as the wart virus, although stable in temperatures of 196° C is more sensitive to heating than cold.

Studies on the effects of heating normal and human papilloma virus (HPV)-infected tissue suggest that it may promote the induction of adaptive immunity [6–10]. Microwave damage to HPV in an in vitro study on genital warts was compared with that caused by treatment with a CO₂ laser. The authors of the work concluded that microwaves were significantly more effective at denaturing HPV than the comparative device [11]. Preliminary studies of human skin explants exposed to low-level microwave energy suggested that increased danger signalling in keratinocytes, including induction of HSP70, may be the critical pathway for cutaneous wart resolution. Microwave-treated keratinocytes were able to induce dendritic cell activation (CD80, CD86, CD40) and enhancement of anti-HPV responses by CD8+ T cells [12, 13]. This case study represents an exciting additional therapeutic option for treatment of recalcitrant cutaneous warts. We acknowledge the limitations of reporting a single case, and further work to address this in a randomised controlled trial setting is underway.

Conclusion

This work represents a single case study of a persistent and painful wart treated successfully using microwave energy applied directly to the lesion using a novel medical device. Further work is required to fully assess the effectiveness of this therapy.

Statement of Ethics

This case study was drawn from an ongoing project which has been granted full ethical approval from the Faculty of Health Sciences, University of Southampton. Full consent was obtained from the patient for use of this case study.

Disclosure Statement

I.R.B. is a consultant for Emblation Medical Limited.

References

- 1 Lynch MD, Cliffe J, Morris-Jones R: Management of cutaneous viral warts. *BMJ* 2014;348:3339–3352.
- 2 Sterling JC, Gibbs S, Haque Hussain SS, Mohd Mustapa MF, Handfield-Jones SE: British Association of Dermatologists' guidelines for the management of cutaneous warts 2014. *Br J Dermatol* 2014;171:696–712.
- 3 Wolf FJ, Grand DJ, Machan JT, Dipetrillo TA, Mayo-Smith WW, Dupuy DE: Microwave ablation of lung malignancies: effectiveness, CT findings, and safety in 50 patients. *Radiology* 2008;247:871–879.
- 4 Matsukawa T, Yamashita Y, Arakawa A, Nishiharu T, Urata J, Murakami R, Takahashi M, Yoshimatsu S: Percutaneous microwave coagulation therapy in liver tumors. A 3-year experience. *Acta Radiol* 1997;38:410–415.
- 5 Karsai S, Daschlein G: "Smoking guns": Hazards generated by laser and electrocautery smoke. *J Dtsch Dermatol Ges* 2012;10:633–636.
- 6 Wang X, Gao XH, Li X, Hong Y, Qi R, Chen HD, Zhang L, Wei H: Local hyperthermia induces apoptosis of keratinocytes in both normal skin and condyloma acuminata via different pathways. *Apoptosis* 2009;14:721–728.
- 7 Zhu L-l, Gao X-H, Qi R, Hong Y, Li X, Wang X, McHepange UO, Zhang L, Wei H, Chen H-D: Local hyperthermia could induce antiviral activity by endogenous interferon-dependent pathway in condyloma acuminata. *Antiviral Res* 2010;88:187–192.
- 8 Ma Y, Huo W, Hong YX, Chen HD, Gao XH: Successful clearance of facial common warts by local hyperthermia: report of two cases. *Dermatol Ther* 2012;25:386–388.
- 9 Huo W, Di ZH, Xiao BH, Qi RQ, Weiland M, Gao XH: Clearance of genital warts in pregnant women by mild local hyperthermia: a pilot report. *Dermatol Ther* 2014;27:109–112.
- 10 Xinghua G, Hongduo C: Hyperthermia on skin immune system and its application in the treatment of HPV-infected skin diseases. *Front Med* 2014;12:9–13.
- 11 Li HX, Zhu W-Y, Xia M-Y: Detection with the polymerase chain reaction of human papillomavirus DNA in condylomata acuminata treated with CO₂ laser and microwave. *Int J Dermatol* 1995;34:209–211.
- 12 Ardern-Jones M, Lee A, Chean LW, Holbrook D, Savelyeva N, Thomson P, Webb C, Polak ME, Bristow IR: Induction of antihuman papillomavirus immunity by microwave treatment of skin. *Br J Dermatol* 2016;175:151.
- 13 Bristow IR, Lim W, Lee A, Holbrook D, Savelyeva N, Thomson P, Webb C, Polak ME, Ardern-Jones MR: Microwave therapy for cutaneous human papilloma virus infection. *Eur J Dermatol*, accepted.

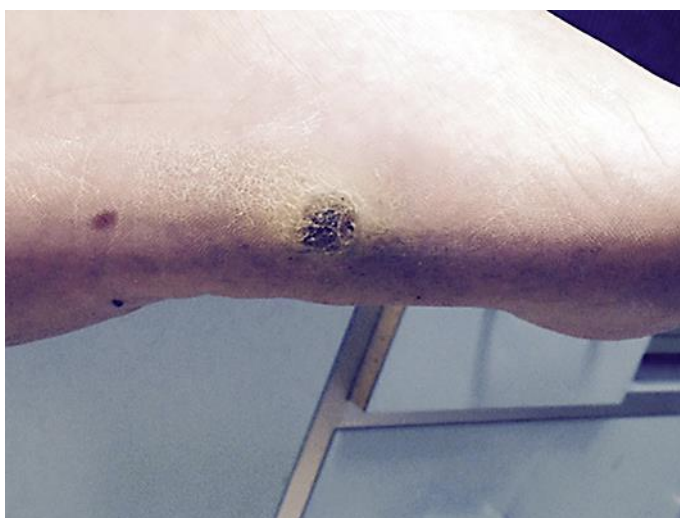

Fig. 1. Lesion at presentation (10 × 10 mm).

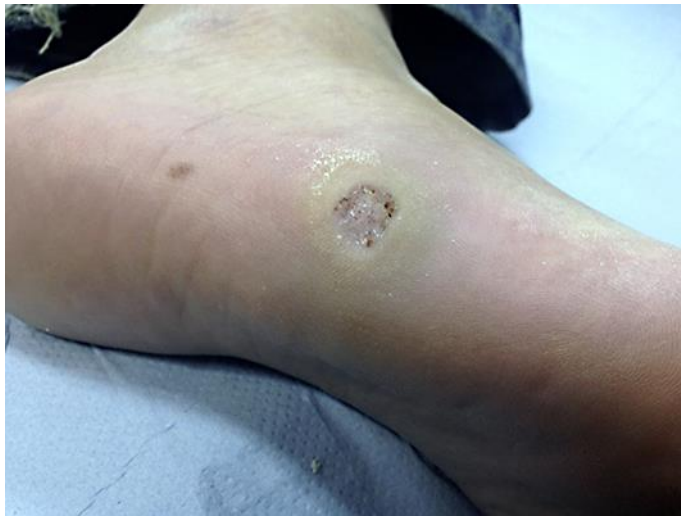

Fig. 2. Lesion at 3 weeks after treatment.

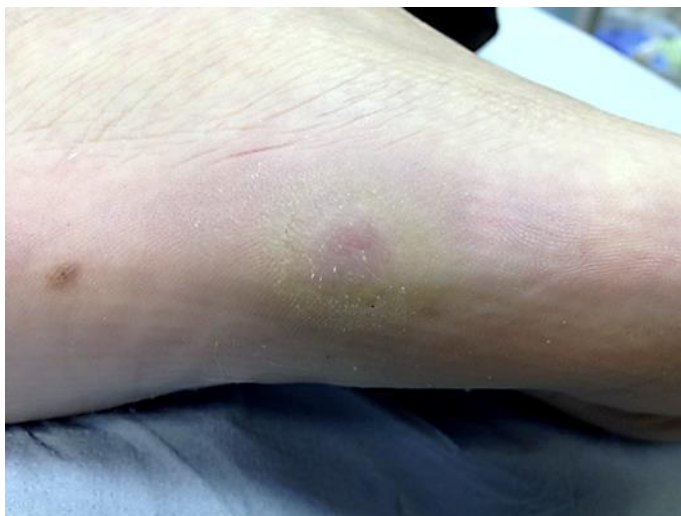

Fig. 3. Lesion at 5 weeks following 2 treatments.

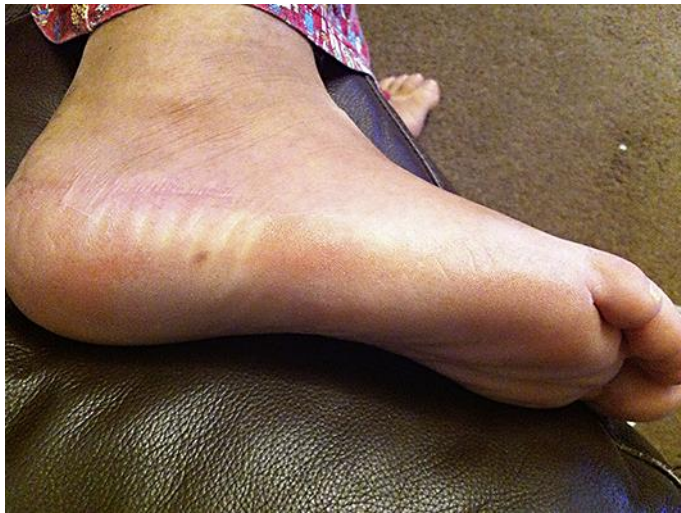

Fig. 4. Lesion resolved at second visit post-operatively.

dermatologist working in close collaboration with the multi-disciplinary BMT team and has been formally operational in our National Health Service Trust since July 2015. Patient reports of the benefit and experiences of services are important when new services are configured. The Outcomes and Experience Questionnaire (OEQ) is a validated tool that brings together into one short instrument questions about two distinct domains – patients' reports of outcomes (OEQ-O score) and their experience (OEQ-E score) of care. Higher OEQ scores represent better outcomes and enhanced experience. A modified OEQ (11 questions) was used to evaluate the dermatology service in the BMT clinic. Questionnaires were self-administered in the haematology outpatients waiting area. Anonymized data were collected over a 2-month period. Overall, there were 35 responses; 23 (66%) had used the dermatology service and 39% reported seeing the dermatologist more than three times. The median OEQ-O score was 18/20 (range 7–20). Seventy-eight percent of responders rated their skin problem after seeing a dermatologist as 'much better'. The median OEQ-E score was 17/18 (range 13–18). Within the experience domain, 100% of responders felt that they were as involved as much as they wanted to be, in decisions about skin care and management. The lowest-scoring item in this domain was regarding information; 57% reported information provided to be extremely helpful. In addition, 34% (n = 12) of responders reported never using the dermatology service. Three-quarters of nonusers were unaware of a dermatology service and half felt that they would benefit from the service but had not yet used it. We have demonstrated the clinical need for a dedicated dermatology service for the BMT clinic. To evaluate the benefits from the patient perspective in terms of outcomes and their experiences of services, the OEQ appears to be an acceptable and valid tool. Overall, OEQ scores were high, supporting the clinician's views that a collaborative working environment in the BMT clinic can optimize management of skin disease following allograft transplantation. Further work to develop patient-focused information relating to management of skin disease may improve the BMT clinic experience.

B114 **Induction of antihuman papillomavirus immunity by microwave treatment of skin**

M. Ardern-Jones,¹ A. Lee,¹ L.W. Chean,¹ D. Holbrook,¹ N. Savelyeva,¹ P. Thomson,² C. Webb,³ M.E. Polak¹ and I. Bristow¹

¹Faculty of Medicine, University of Southampton, Southampton, U.K.; ²The Podiatry Centre, Portsmouth, U.K. and ³The Podiatry Centre, Dunfermline, U.K.

Human papillomavirus (HPV) is a virulent human pathogen that can be associated with induction of malignancy. However, cutaneous infection of keratinocytes can also result in long-lived HPV infection in the epidermis, with consequent epithelial hyperplasia (cutaneous warts). Current treatment options for HPV skin infection show only modest benefit for cutaneous warts. Hand held microwave devices have recently

been developed and may offer new therapeutic options for the treatment of skin lesions. We aimed to test the hypothesis that microwave therapy could induce anti-HPV immune responses. Explant human skin models and keratinocyte monolayers were utilized to investigate the effects of microwave treatment of human skin. At low energy levels, microwave effects on human skin showed minimal architectural change, whereas at higher energy levels, significant tissue destruction was observed in a dose-dependent manner. Keratinocytes normally reside in a nonactivated state; however, those from microwave-treated human skin were found to show increased signalling through danger-associated molecular patterns, including heat shock protein-70, and even at low energy levels were able to induce dendritic cell activation (CD80, CD86, CD40) and enhance presentation of HPV peptides to CD8⁺ T cells with consequent interferon- γ production. However, this effect was not seen following liquid nitrogen cryotherapy treatment of controls. In a pilot study, 32 consecutive individuals with 52 recalcitrant HPV infections (cutaneous warts) were treated with a novel hand held microwave device (Swift; Emblation Medical, Alloa, U.K.). Low-energy microwave therapy to the skin induced minimal tissue inflammation, the treatment was well tolerated, and 76% of lesions cleared. These data show that microwave induction of skin dendritic cells regulated CD8⁺ immunity via keratinocyte signalling. This study provides evidence to support the utility of microwave therapy in the induction of anti-HPV responses in the skin, which offers a promising approach for the treatment of cutaneous HPV infections. This work was funded by an unrestricted educational grant from Emblation Medical Ltd.

Posters

B115 **A chronic wound in the setting of sclerodermoid graft-versus-host disease and radiation necrosis** S. Menzies, C. Healy, M. McMenamin and R. Barry

St James's Hospital, Dublin, Ireland

We present the case of a 64-year-old man with a background history of a sibling donor allogeneic bone marrow transplant for myelodysplasia in January 2013. His recovery was uneventful apart from mild steroid-responsive liver graft-versus-host disease (GVHD). One year following transplantation he developed a large nodule at his sternal notch. Histology showed an incompletely excised squamous cell carcinoma with perineural invasion. He subsequently had two-stage Mohs micrographic surgery requiring 13 blocks and a staged split-thickness skin graft in July 2014. Following MDT discussion, adjuvant radiotherapy was advised. He went on to receive 60 Gy radiotherapy (30 fractions) to the postoperative bed in

Case Report

Successful Treatment of Hard Corns in Two Patients Using Microwave Energy

Ivan R. Bristow^a Christopher J. Webb^b

^aThe Chiropody Surgery, Lymington, UK; ^bThe Podiatry Centre, Cosham, Portsmouth, UK

Keywords

Plantar corns · Microwave energy · Pain

Abstract

Corns are a common foot problem accounting for nearly half of all problems seen within podiatry and chiropody clinics. Hard corns are concentrated areas of hyperkeratosis within the stratum corneum, typically found on the weight-bearing (plantar) surfaces of the feet. For many patients, they are a source of pain and have been shown to negatively affect a patient's activity and quality of life. Most of the currently available treatments are short-lived in their effectiveness, with corns frequently being recurrent, requiring repeated visits to remove the painful lesions. The use of handheld microwave devices indicated for surface applications has demonstrated effectiveness in clearing recalcitrant plantar warts and significantly reducing the pain associated with them. The authors report 2 cases of patients with persistent and painful plantar corns who underwent microwave treatment of their plantar corns with a successful, lasting reduction in pain levels after the intervention. Further work is required to fully assess the potential of this treatment modality in the management of painful plantar corns.

© 2020 The Author(s)
Published by S. Karger AG, Basel

Introduction

Corns are a common foot problem thought to affect between 10 and 48% of adults [1, 2]. Typically, they present as hard, yellow hyperkeratotic lesions, located in areas of the foot subjected to pressure. Their exact aetiology remains unclear; however, the intermittent forces generated during locomotion and by shoe wear are known to increase shear and frictional forces across the foot, which in turn leads to the development of thickening of the stratum corneum (hyperkeratosis), which may develop into symptomatic corns – most frequently located under the metatarsal heads and on the lateral side of the fifth toe.

Their presence can lead to pain, a decrease in physical function and a reduction in the patient's quality of life [3]. Smokers are known particularly to develop painful plantar lesions [4]. Traditional treatment of plantar corns focuses on elimination of the causative factors, where possible, but for many patients they can take a chronic course. Within chiropody and podiatry clinics, removal of the corn using a scalpel (enucleation) is a favoured procedure which has been shown to give immediate short-term relief of pain [5]. Consequently, for many patients, due to the recurrent nature of corns, repeat visits to the podiatrist/chiropodist for treatment are necessary to reduce the pain associated with them.

In a previously published study, a handheld microwave device indicated for the treatment of surface skin lesions was shown, in a cohort of 32 adult patients, to resolve stubborn plantar warts. One finding from this work suggested a significant decrease in pain levels associated with their warts whilst undergoing treatment with microwaves [6]. Histologically, corns and warts both represent potentially painful hyperkeratotic lesions.

Case Presentation

Patient A was a 50-year-old construction worker. His medical history showed occasional migraines, for which he took sumatriptan (25 mg), but he was otherwise in good health. He had smoked 10 cigarettes a day for many years. He had a history of two small, plantar corns on his left foot which had been present for years (Fig. 1). He was receiving monthly podiatry appointments for scalpel reduction of the corns to relieve the pain. Prior to the current treatment regime, he had tried prescription insoles to redistribute pressure away from the painful areas of the foot and the application of salicylic acid corn plasters. The latter had led to irritation of the skin, so consequently it was discontinued by the patient.

Following a discussion with the patient and consent, it was decided to embark on a course of microwave treatment using the SWIFT[®] microwave device (Emblation, UK). A course of treatment was proposed using microwave treatment given at monthly intervals for up to 4 months. At each appointment visit, prior to debridement, both plantar corns were cleaned using chlorohexidine gluconate in 70% alcohol and enucleated with a scalpel. The microwave device was then placed onto each of the two corns, and 10 W of energy was delivered for 2 s – a total of 20 J of energy was delivered into each lesion at each visit. At each visit, the patient was also asked to rate the pain in the week prior to treatment on a scale of 0–10 (with 0 = no pain, 10 = the worst pain imaginable).

Prior to the first application of treatment, the patient had rated the pain as 6 out of 10. On subsequent visits the pain score reduced to a score of 1. A month after the fourth application of microwaves, the patient reported no pain (score of 0) from the corn in the previous week. After completion of treatment, he extended his appointment intervals to 12 weeks with no active further treatment. At his review 6 months after the last treatment, he reported that

although they were still present, the corns were no longer painful (Fig. 2). He was advised to return should they become painful again, but did not return to the clinic after this appointment.

Patient B was a 77-year-old female with a painful corn of 20 years duration on the lateral apex of her third toe (Fig. 3). She was in good health and receiving no medication. Her corn was being treated with fortnightly scalpel debridement by her podiatrist, but despite this the patient reported the pain as a constant problem affecting her daily activities. Following a discussion with the patient, a course of microwave treatment was suggested. Prior to treatment, the patient had rated the pain from her corn as 7 out of 10 (0 being no pain, 10 the worst pain imaginable). The lesion was cleaned with 70% alcohol and underwent scalpel debridement. Following this, the corn was treated using microwaves – a single application of 8 W for 2 s, 5 times. She was re-booked to return after 2 weeks. At this appointment, she reported a significant pain reduction (to 4 out of 10). A subsequent repeat treatment of 8 W for 2 s, applied 5 times, was carried out. Four weeks later, her pain level had reduced to 1 out of 10 and the treatment with microwaves was repeated (8 W applied to the corn for 2 s, 5 times). The patient was reviewed after 3 treatments and reported no further pain from the lesion (Fig. 4). At 6 months, although still present, the corn was still entirely pain free.

Discussion and Conclusion

The use of a handheld microwave device in the treatment of plantar warts showed a clearance rate of nearly 76% in adults with recalcitrant lesions. The data from this work highlighted how following treatment of painful warts using microwaves, there was a significant reduction in reported pain scores in the majority of participants [6]. Both corns and plantar warts are hyperkeratotic lesions of the epidermis exhibiting similar features – hyperkeratosis of the stratum corneum and pain are frequently associated with their presence.

Microwaves are a form of energy within the electromagnetic spectrum (300 MHz to 300 GHz). A review of the effects of electromagnetic energy on human tissue has reported a number of such effects, including pain relief, which may contribute to the positive outcome observed in these patients [7]. Despite the reduction in pain, both our patients remained with pain-free corns, suggesting that the effect was likely based on alteration of the local pain mechanisms rather than on pain relief through eradication of the lesions. Even though the exact mechanism is unknown, there are several theories which may help explain the observed effect.

Research has shown that in peripheral nerve fibres, raising of the skin temperature is accompanied by an increase in nerve conduction velocity with a concomitant decrease in sensory latency. The nerve conduction velocity increases, and this is thought to be related to nerve denervation or an increase in the pain threshold [8]. It is known that use of this microwave device on skin can increase local skin temperatures in the hyperthermic range of 46°C [9], which may give rise to localised nerve denervation and a subsequent reduction in pain.

A review of the effects of pulsed electromagnetic fields has been undertaken, and at a cellular level, it has been shown how the modality causes an increase in calcium binding to calmodulin, which in turn promotes nitric oxide release, which induces the effect of pain relief. In addition, levels of the proinflammatory cytokine IL-1 β have been shown to be lower in those patients receiving electromagnetic energy treatment [10]. This cytokine has been shown to be stimulatory in the induction of pain following nerve injury.

However, further work is required to assess this effect seen with microwaves on a larger study population as a potential modality for the treatment of painful plantar corns.

Statement of Ethics

This work complies with the guidelines for human studies and was conducted ethically in accordance with the World Medical Association Declaration of Helsinki. The patients have given their written informed consent to publish their case (including publication of images).

Conflict of Interest Statement

I.R.B. is a consultant for Emblation Limited. C.J.W. has no conflicts of interest to declare.

Funding Sources

The manufacturer of the microwave device has provided payment for the article processing fee for this article.

References

- 1 Burzykowski T, Molenberghs G, Abeck D, Haneke E, Hay R, Katsambas A, et al. High prevalence of foot diseases in Europe: results of the Achilles Project. *Mycoses*. 2003 Dec;46(11-12):496–505.
- 2 Farndon L, Vernon W, Parry A. What is the evidence for the continuation of core podiatry services in the NHS: a review of foot surveys. *Br J Podiatr*. 2006;9:89–94.
- 3 Farndon L, Concannon M, Stephenson J. A survey to investigate the association of pain, foot disability and quality of life with corns. *J Foot Ankle Res*. 2015 Dec;8(1):70.
- 4 Merrill TJ, Vena V, Rodrigues LA. Relationship between smoking and plantar callus formation of the foot. Podiatry Institute; 2012.
- 5 Gijón-Noguerón G, García-Paya I, Morales-Asencio JM, Jiménez-Cebrián A, Ortega-Ávila AB, Cervera-Marín JA. Short-term effect of scalpel debridement of plantar callosities versus treatment with salicylic acid patches: the EMEDESCA randomized controlled trial. *J Dermatol*. 2017 Jun;44(6):706–9.
- 6 Bristow I, Lim WC, Lee A, Holbrook D, Savelyeva N, Thomson P, et al. Microwave therapy for cutaneous human papilloma virus infection. *Eur J Dermatol*. 2017 Oct;27(5):511–8.
- 7 Guo L, Kubat NJ, Isenberg RA. Pulsed radio frequency energy (PRFE) use in human medical applications. *Electromagn Biol Med*. 2011 Mar;30(1):21–45.
- 8 Kelly R, Beehn C, Hansford A, Westphal KA, Halle JS, Greathouse DG. Effect of fluidotherapy on superficial radial nerve conduction and skin temperature. *J Orthop Sports Phys Ther*. 2005 Jan;35(1):16–23.
- 9 Bristow IR, Ardern-Jones M. Treating verrucae effectively with microwave energy – are we getting warmer? *Podiatry Now*. 2017;20(6):21–3.
- 10 Strauch B, Herman C, Dabb R, Ignarro LJ, Pilla AA. Evidence-based use of pulsed electromagnetic field therapy in clinical plastic surgery. *Aesthet Surg J*. 2009 Mar-Apr;29(2):135–43.

The authors contributed equally to the manuscript

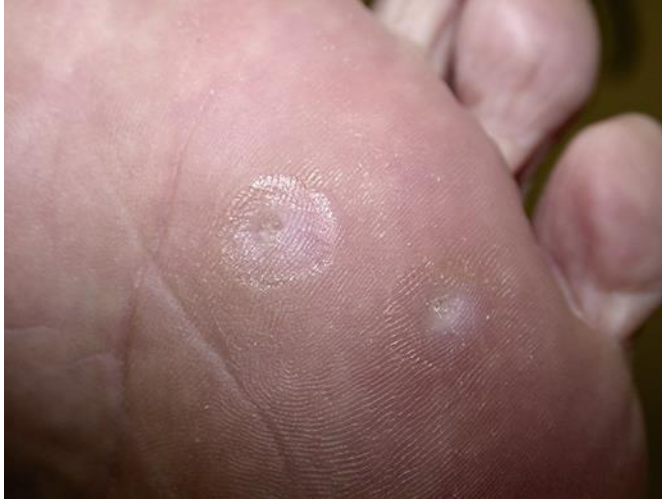

Fig. 1. Patient A: plantar corns prior to microwave treatment.

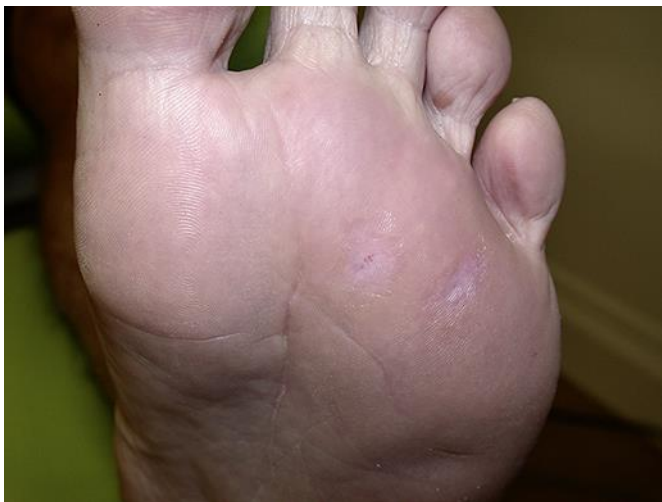

Fig. 2. Patient A: plantar corns at the 6-month review after completion of treatment.

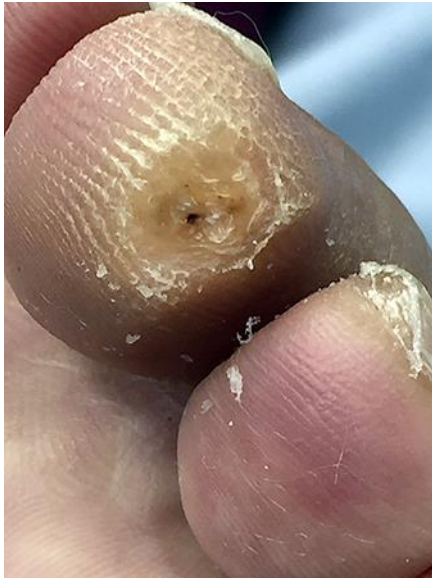

Fig. 3. Patient B: apical corn at presentation.

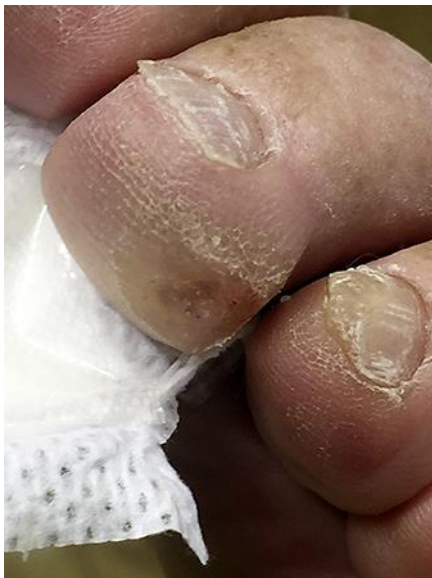

Fig. 4. Patient B: after 3 microwave treatments.